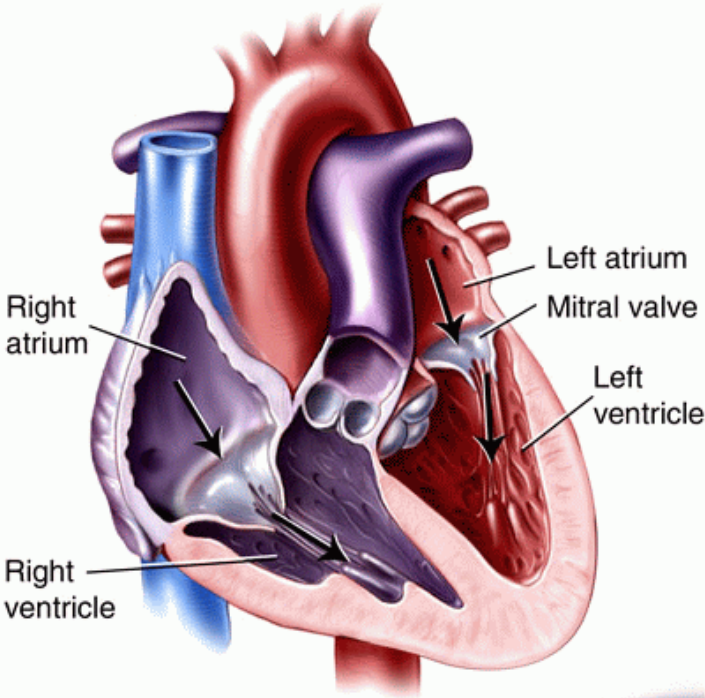
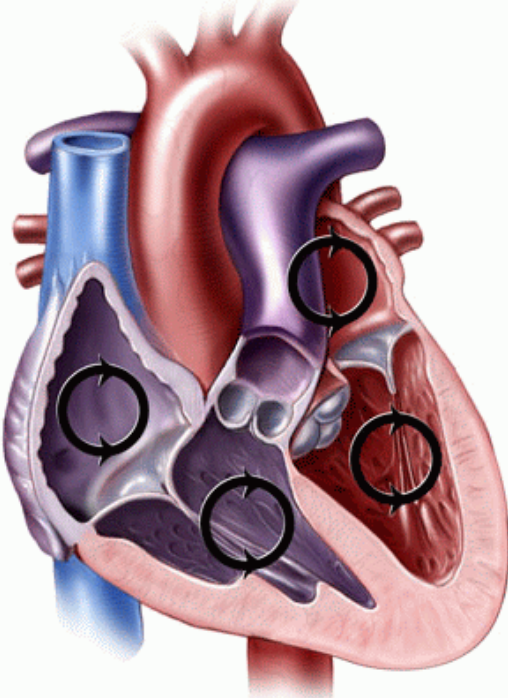


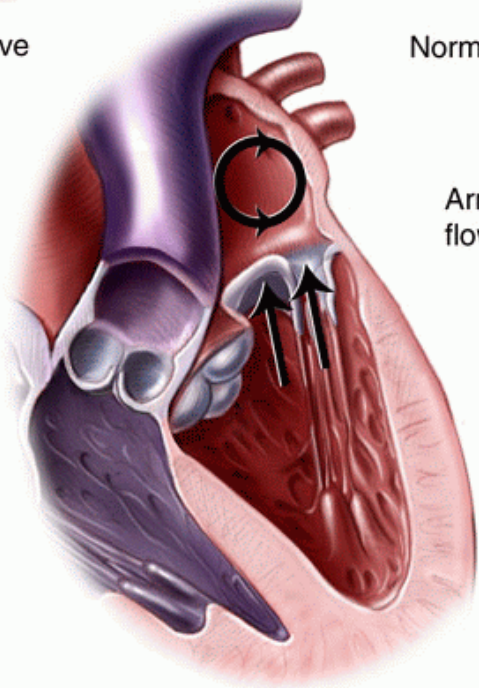
Mitral Valve: Normal and Prolapsed



Normal open mitral valve



Normal closed mitral valve



Prolapsed mitral valve (blood flows backward into atrium)